

## POST-OPERATIVE MANAGEMENT OF ALLERGIC FUNGAL SINUSITIS (ASF): ROLE OF ITRACONAZOLE

Kanchan S. Dhote<sup>1</sup>, Priti R. Dhoke<sup>2</sup>, V. V. Harkare<sup>3</sup>, N. V. Deosthale<sup>4</sup>, Sonali P. Khadakkar<sup>5</sup>

### HOW TO CITE THIS ARTICLE:

Kanchan S. Dhote, Priti R. Dhoke, V. V. Harkare, N. V. Deosthale, Sonali P. Khadakkar. "Post-Operative Management of Allergic Fungal Sinusitis (ASF): Role of Itraconazole". Journal of Evolution of Medical and Dental Sciences 2014; Vol. 3, Issue 32, August 04; Page: 8729-8734, DOI: 10.14260/jemds/2014/3114

**ABSTRACT: AIM:** To present experience of Itraconazole as an adjunct to steroids in management of post-operative patients of Allergic fungal sinusitis. **SETTINGS AND DESIGN:** Prospective clinical study for a period of 2 years on 60 patients with a mean follow up of 6 months was carried out in tertiary health care centre. **MATERIALS AND METHODS:** All the patients who were clinically diagnosed as Allergic fungal sinusitis and underwent surgery for the same were divided randomly into two groups. Group A (n=30) were put on oral Itraconazole additionally as compared to patients of group B (n=30). The patients of both the groups were followed up periodically at 1month, 2month and 6 months. **STATISTICAL ANALYSIS:** Risk of recurrence was calculated in both the groups. **RESULT:** It was found that the risk of recurrence was double in group B as compared to group A. Systemic Itraconazole is an effective adjunct to systemic and topical steroid therapy during the early postoperative course of management of Allergic fungal sinusitis.

**KEYWORDS:** Sinusitis, mucin, polyp, fungi.

**INTRODUCTION:** Allergic fungal sinusitis (AFS) was recognized more than two decades ago and is still a debatable topic because of its diagnostic and therapeutic controversies. Initially it was assumed that the offending agent is invasive and hence aggressive surgical as well as systemic antifungal medicines like Amphotericin-B etc. were instituted, but still the recidivism remained high.

It is now believed that AFS has an etiology similar to that of allergic bronchopulmonary aspergillosis (ABPA) involving both immediate and delayed hypersensitivity reactions.<sup>1</sup> T Robson et al<sup>2</sup> in 1989 introduced the term Allergic fungal sinusitis (or allergic fungal rhino sinusitis) to describe a constellation of unusual findings in a unique group of patients suffering from chronic sinusitis. There are multiple factors which lead to the development of AFS.

It is initiated when an atopic individual is exposed to inhaled fungus which gets deposited in the sinus cavity leading to escalating immunological reaction, "the Gel & Coombs reaction Type I" which leads to mucosal edema, stasis of secretions and inflammatory exudates. All these combine to cause obstruction of the sinus ostia. The resulting obstruction of sinus ostia and stasis within the sinuses creates an environment, ideal for the fungus to proliferate and cause increased immunologically mediated inflammation.

Bent and Kuhn<sup>3</sup> in 1996 outlined the Clinicopathological features of AFS patients. They came out with 11 findings, out of which 5 were common to all the patients which were referred to as major criterias.

They were Type I hypersensitivity, nasal polyposis, characteristic CT scan findings, positive fungal stain/ culture and allergic mucin with fungal elements. According to Ponikau JU et al<sup>4</sup> the diagnostic criteria for AFS in patients with chronic sinusitis with/ without polyposis is presence of eosinophils in allergic mucin and not Type I hypersensitivity. Allergic fungal rhinosinusitis shows

## ORIGINAL ARTICLE

---

characteristic findings on CT scan. There are central areas of hyper attenuation of various patterns like star filled sky within the sinus cavity corresponding to areas of hypo intensity on T1 weighted MR images and signal void on T2 weighted MR images. These central areas represent protienacious allergic mucin.

Fungal cultures of allergic fungal mucin provides some evidence helpful in diagnosis but it is important to realize that the diagnosis of AFS is not established or eliminated based on the results of these cultures.

Based upon this rudimentary understanding of AFS, treatment plans according to its multiple contributing factors have emerged. Medical control of the disease has made use of various combinations of antifungal medications, corticosteroids and immunotherapy with varying degrees of disease control.

The single invariable component of the combination therapy however has remained surgical removal of the inciting fungal allergic mucin and polyps. This study addresses the current role of antifungal itraconazole in the management of nasal counterpart of ABPA (Allergic Bronchopulmonary Aspergillosis) i.e. AFS (Allergic Fungal Sinusitis) as an adjuvant modality to surgery for decreasing recurrence rates.

**Patients and Methods:** In a prospective clinical study carried out in tertiary health care centre of central India for a period of 2 years, 60 patients who underwent FESS for Allergic Fungal Sinusitis were followed up for a period of 6 months. A few of the patients included were having recurrent disease.

All the patients were subjected to the following protocol. After clinical evaluation in the OPD by anterior rhinoscopy and diagnostic nasal endoscopy (DNE) using 4 mm fiberoptic 0°, 30° sinus endoscope, and the diagnosis was made. All suspected patients preoperatively underwent routine blood and urine examination, radiological examination including X-ray paranasal sinuses and CT Scan of PNS.

All patients underwent FESS (Functional Endoscopic Sinus Surgery) alone or in few difficult cases along with FESS, external ethmoidectomy or Caldwell Luc was also performed, after taking a prior informed consent.

Intraoperatively the findings of multiple polyps, allergic mucin, fungal debris and mucosal edema confirmed the diagnosis. Specimen of Mucin and fungus was sent for stain/ culture and polyps for histopathology examination to rule out malignancy and inverted papilloma.

Post-operatively all the patients were subjected to liver transaminases levels. These 60 patients were then alternatively put in 2 groups (A and B). All the patients post operatively received antibiotics, antihistamines and analgesic for 5 days and after pack removal fluticasone nasal spray 2 puffs twice daily in both nostrils for 6 months was given.

In addition to this group A patients also received oral Itraconazole 100 mgs twice a day for 6 weeks. Liver transaminases were checked after 1 months of therapy. Only 1 patient had marginally raised levels and was discontinued from itraconazole treatment. Alkaline nasal douche was advised to all for 2-3 months.

Follow up of average 6 months was done for all patients, and they visited ENT OPD on 5<sup>th</sup> day, 1 mth, 2 mths and 6 mths postoperatively. They all underwent check endoscopy using 0° & 30° sinus

## ORIGINAL ARTICLE

---

endoscopes in OPD. The patients were graded according to Kupferber's grading system<sup>5</sup>. And their findings were documented as below:

Stage-0:	No mucosal edema or allergic mucin
Stage-I:	Mucosal edema with/without allergic mucin
Stage-II:	Polypoidal edema with or without mucin
Stage-III:	Sinus polyps with fungal debris or allergic mucin

**RESULT:** In our study, 60 patients were included, 72.5% of which were females and 27.5% male and the age group of patients varied from 21 years to 60 years. All the patients presented clinically with nasal obstruction and discharge, 60% had hyposmia to anosmia and sneezing. On anterior rhinoscopy there were polyps, thick mucoid secretions and in few frank fungus on diagnostic nasal endoscopy.

A computerized tomography scan of paranasal sinuses were done in all the patients (Fig. 1). Pan-sinusitis was seen in 62.5% patients and 87.5% patients had demonstrable characteristic opacities in the sinuses to suggest presence of fungus.

All the patients underwent FESS (Functional Endoscopic Sinus Surgery) while 4 also underwent Caldwell Luc and 1 patient needed external ethmoidectomy for extensive diseases in maxillary and frontoethmoidal sinuses respectively. More than 80% patients had a combination of polyps, fungus and greenish brown mucin (Fig. 2).

In our study over a mean period of follow up at six months all patients of group A showed symptomatic improvement (most of them were completely relieved and some improved), while in group B the number of patients who showed some symptomatic improvement, were more than the patients showing complete relief. (Table 1)

Histopathology examination of the postoperative specimen was done. One patient was diagnosed as inverted papilloma with allergic polyp. Fungal culture was positive for *Aspergillus fumigatus* in 25% of the patients while others had no growth. 83.3 % patients of group A (who took itraconazole) showed great improvement while 16.6% showed variable stages of recurrences with no patients showing grade III recurrence at the end of 6 months. Endoscopic cleaning was done at each visit and patients kept under follow-up (Fig. 3).

13 patients (43.33%) of group B had recurrence at the end of 6 months follow up. Out of which 5 patients who were in grade II & III had been started on oral steroids at the end of 6 months (Table 2).

Risk of recurrence was calculated for both the groups and it was found that the risk was almost double i.e. 59.52% for group 'B' patients as compared to 27.78% for group 'A' patients (table 3). The chi-square value derived was 5.079 with a p-value of 0.025 (<0.05 is significant). Hence there is a significant improvement in the outcome of results if itraconazole is used as an adjunctive treatment of AFS postoperatively.

The need for revision surgery is avoided and the dose of oral steroids needed is also decreased. Postoperatively out of 2492 doses of itraconazole administered no significant side effects were encountered. In only one patient due to marginally raised transaminases levels at one month follow up itraconazole was not given further.

**DISCUSSION:** In this study, two-thirds i.e. 80% of the patients had polyps, fungus and allergic mucin intraoperatively, 5% had fungus with allergic mucin and edematous mucosa. Combination of allergic

## ORIGINAL ARTICLE

---

mucin with only polyps was seen in the rest of the 15% patients. 95% had polyps in our series. Allergic mucin was seen in all.

The incidence of polyposis in Allergic fungal rhinosinusitis according to Schubert M S et al<sup>6</sup> was almost 100 %.

Rains et al<sup>7</sup> in there 12 year retrospective study suggested that the use of itraconazole, low-dose oral corticosteroids, topical corticosteroids, and endoscopic surgery are safe and clinically effective regimen in the management of AFS. In their clinical experience medical management of recurrent AFS with itraconazole avoid revision surgery.

According to Andese et al<sup>8</sup> most patients experience remittent AFS disease despite corticosteroid therapy and aggressive sinus surgery. Antifungal therapy has a definite adjunctive role in the treatment of ABPA according to many controlled trials. Its use in their long-term study on a young man with remittent AFS broke the cycle of relapsing disease.

Systemic steroids have many adverse effects like osteoporosis, cataracts, glaucoma and avascular necrosis of hip. It may also complicate the treatment of diabetes and hypertension and lead to recrudescence of peptic ulcer disease in predisposed individuals

According to Lebeau B et al,<sup>9</sup> Itraconazole has got a definite adjunctive role in the management of ABPA and is relatively safe. It leads to better control of Asthma, improvement in lung function and reductions in systemic doses of steroids.

**CONCLUSION:** Weighing the benefits of itraconazole over its minimal side effects as compared to oral steroids the use of itraconazole in patients with AFS postoperatively for short period and in low doses is advisable. Itraconazole may prolong the time to next recurrence and may enable the patient to significantly decrease or stop oral steroids<sup>10</sup>.

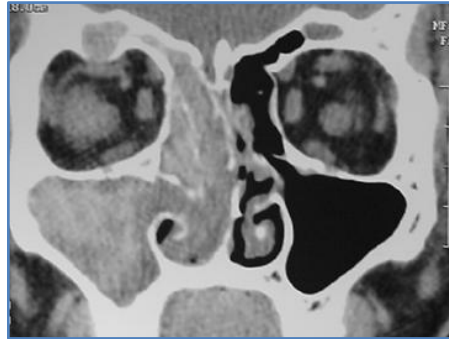
### REFERENCES:

1. Katzenstein AL, Sale SR, Greenlurger PA. Pathologic findings in *Aspergillus* sinusitis. A newly recognised form of sinusitis. *Am J Surg Pathol.* 1983 Jul; 7(5): 439-43.
2. Robson JM, Hogan PG, Benn RA, Gatenby PA. Allergic fungal sinusitis presenting as a paranasal sinus tumor. *Aust Nz J Med.* 1989 Aug; 19 (4): 351-3.
3. Bent JP, Kuhn FA. Antifungal activity against allergic fungal sinusitis organism. *Laryngoscope.* 1996; 106: 1331-1334.
4. Ponikau JU, Shoovis DA, Kern EB, Homburger HA, Frigas E, Gaffiy TA, Roberts GD. The diagnosis & incidence of allergic fungal sinusitis. *Mayodin Proc.* 1999 Sept; 74 (a): 877-84.
5. Kupferberg SB, Bent JP 3<sup>rd</sup>, Kuhn FA. Prognosis of allergic fungal sinusitis. *Otolaryngol Head Neck Surg.* 1997 Jul; 117 (1): 35-41.
6. Schubert MS, Goetz DW. Evaluation and treatment of Allergic Fungal Sinusitis I Demographics and diagnosis. *J Allergy Clin Immunol.* 1998; 102: 387 – 394.
7. Rains BM 3<sup>rd</sup>, Mineck CW. Treatment of Allergic Fungal Sinusitis with high dose itraconazole: *Am J Rhinol.* 2003 January – February; 17(1): 1 – 8.
8. Andes D, Proctor R, Bush RK, Paste TR. Report of successful prolonged antifungal therapy for refractory allergic fungal sinusitis. *Clin infect Dis.* 2000 Jul; 31(1): 202-4.
9. Lebeau B, Pinel C et al. Itraconazole in the treatment of aspergillosis-A study of 16 cases. *Mycoses.* 1994; 37:171-9.

## ORIGINAL ARTICLE

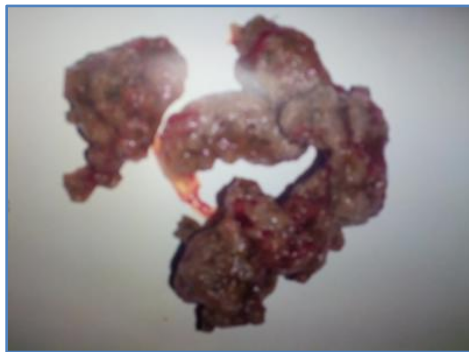
10. Seiberling K, Wormald PJ. The role of itraconazole in recalcitrant fungal sinusitis. *Am J Rhinol Allergy*. 2009 May-June; 23 (3): 303-6.

Figure 1: Coronal section of CT scan PNS showing soft tissue densities in right side of frontals, ethmoids and maxillary sinuses with areas of hyperattenuation suggesting fungus.



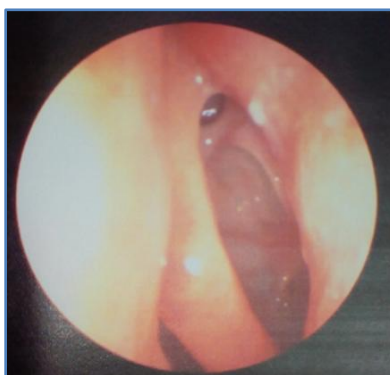**Fig. 1**

Figure 2: Specimen of the fungus removed during surgery.



**Fig. 2**

Figure 3: Endoscopic view 6 months postoperatively showing healthy maxillary ostium and ethmoidal cavity without any signs of recurrence.



**Fig. 3**

## ORIGINAL ARTICLE

Symptoms	Complete relief (%)		Better (%)		Same (%)		Worst (%)	
	A	B	A	B	A	B	A	B
Groups								
Nasal obstruction	87.8	12.5	12.12	87.5	0	0	0	0
Nasal discharge	87.8	12.5	12.12	87.5	0	0	0	0
Sneezing	79.16	0	20.83	100	0	0	0	0
Postnasal drip	100	100	0	0	0	0	0	0
Smell disturbance	43.47	0	47.28	62.5	8.6	37.5	0	0
Headache	85.7	100	14.28	0	0	0	0	0

**Table 1: Summary of follow up of patient satisfaction in group A and group B at 6 months**

Stage	1 Month		2 Month		6 Month	
	Group A	Group B	Group A	Group B	Group A	Group B
0	23	17	24	18	25	17
I	3	4	5	6	3	8
II	3	2	2	3	2	3
III	1	7	0	3	0	2

**Table 2: Comparison of Endoscopic Follow-up of Group A and B patients**

	Recurrence	No recurrence	Risk of recurrence
<b>Group A</b>	5	25	27.78%
<b>Group B</b>	13	17	59.52%

**Table 3: Comparison of risk of recurrences in Group A and Group B patients**

$X^2=5.079$  p value = 0.024 (significant <0.05)

### AUTHORS:

1. Kanchan S. Dhote
2. Priti R. Dhoke
3. V. V. Harkare
4. N. V. Deosthale
5. Sonali P. Khadakkar

### PARTICULARS OF CONTRIBUTORS:

1. Assistant Professor, Department of ENT, NKP SIMS & Lata Mangeshkar Hospital & Research Centre, Digdoh Hills, Hingna Road, Nagpur.
2. Lecturer, Department of ENT, NKP SIMS & Lata Mangeshkar Hospital & Research Centre, Digdoh Hills, Hingna Road, Nagpur.
3. Professor and HOD, Department of ENT, NKP SIMS & Lata Mangeshkar Hospital & Research Centre, Digdoh Hills, Hingna Road, Nagpur.
4. Professor, Department of ENT, NKP SIMS & Lata Mangeshkar Hospital & Research Centre, Digdoh Hills, Hingna Road, Nagpur.

5. Assistant Lecturer, Department of ENT, NKP SIMS & Lata Mangeshkar Hospital & Research Centre, Digdoh Hills, Hingna Road, Nagpur.

### NAME ADDRESS EMAIL ID OF THE CORRESPONDING AUTHOR:

Dr. Kanchan S. Dhote,  
46, Sainath Nagar,  
Bhamti, Nagpur-440022.  
Email: kanchandhote@rediffmail.com

Date of Submission: 17/07/2014.  
Date of Peer Review: 18/07/2014.  
Date of Acceptance: 28/07/2014.  
Date of Publishing: 01/08/2014.